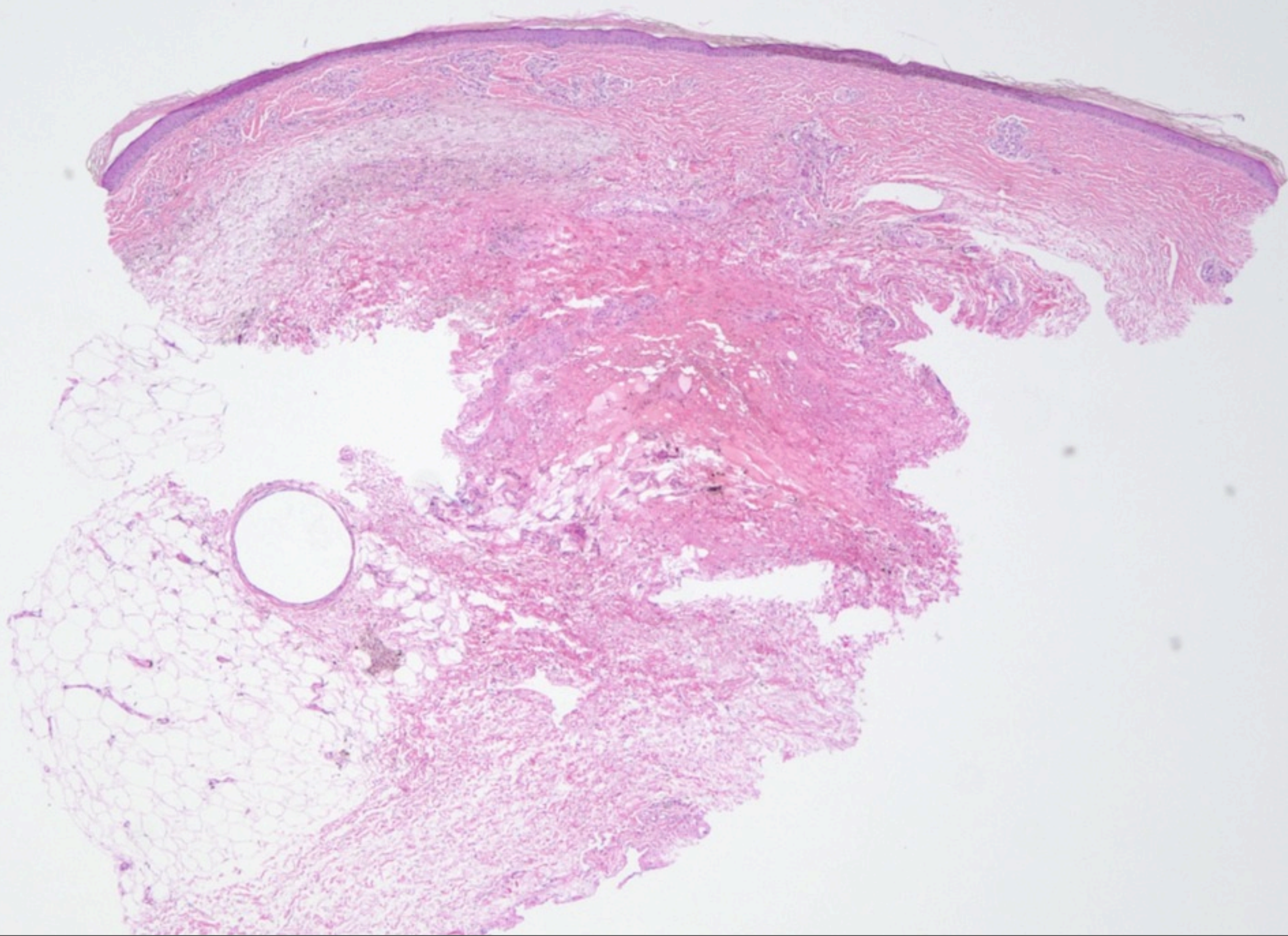
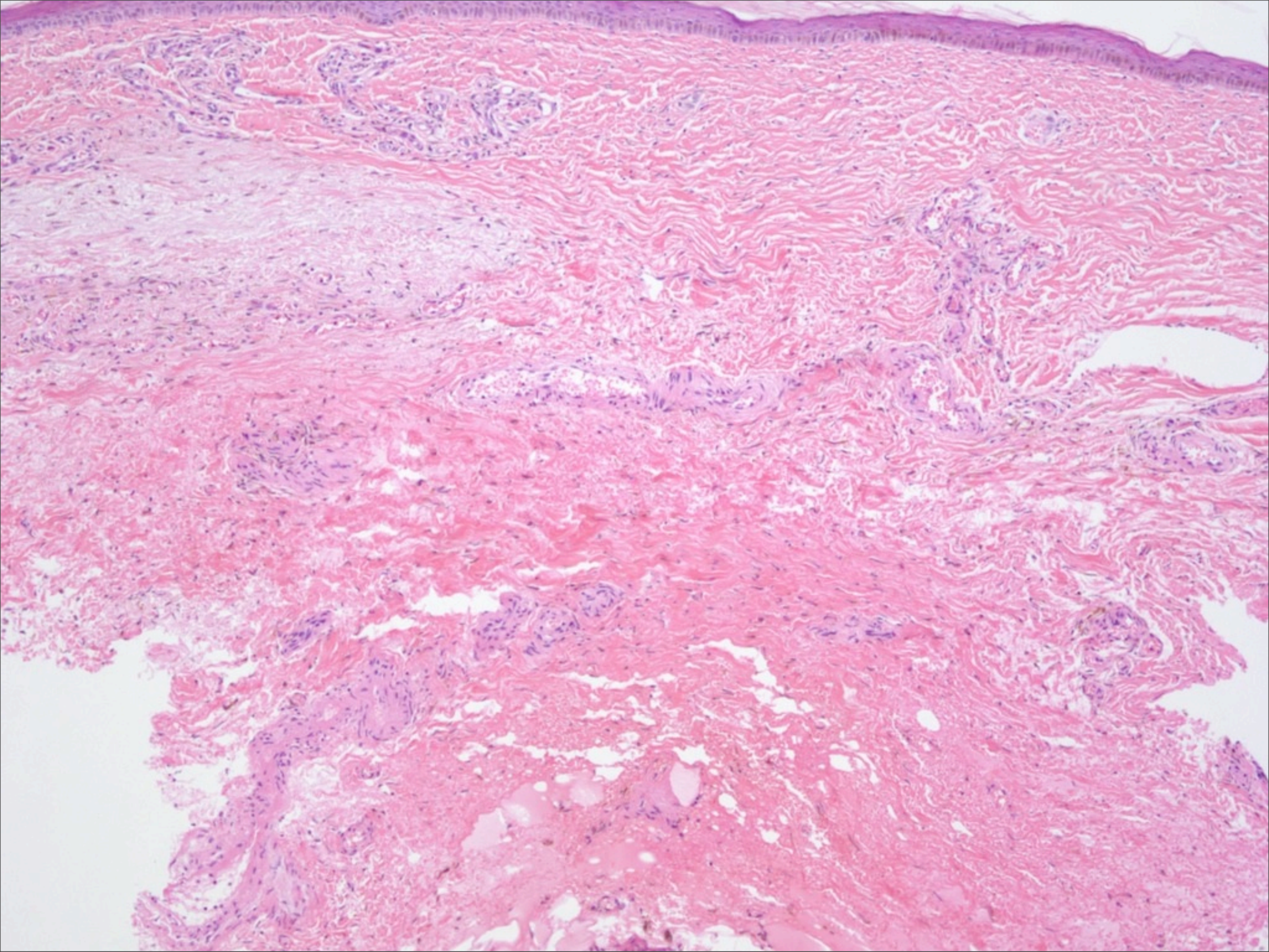
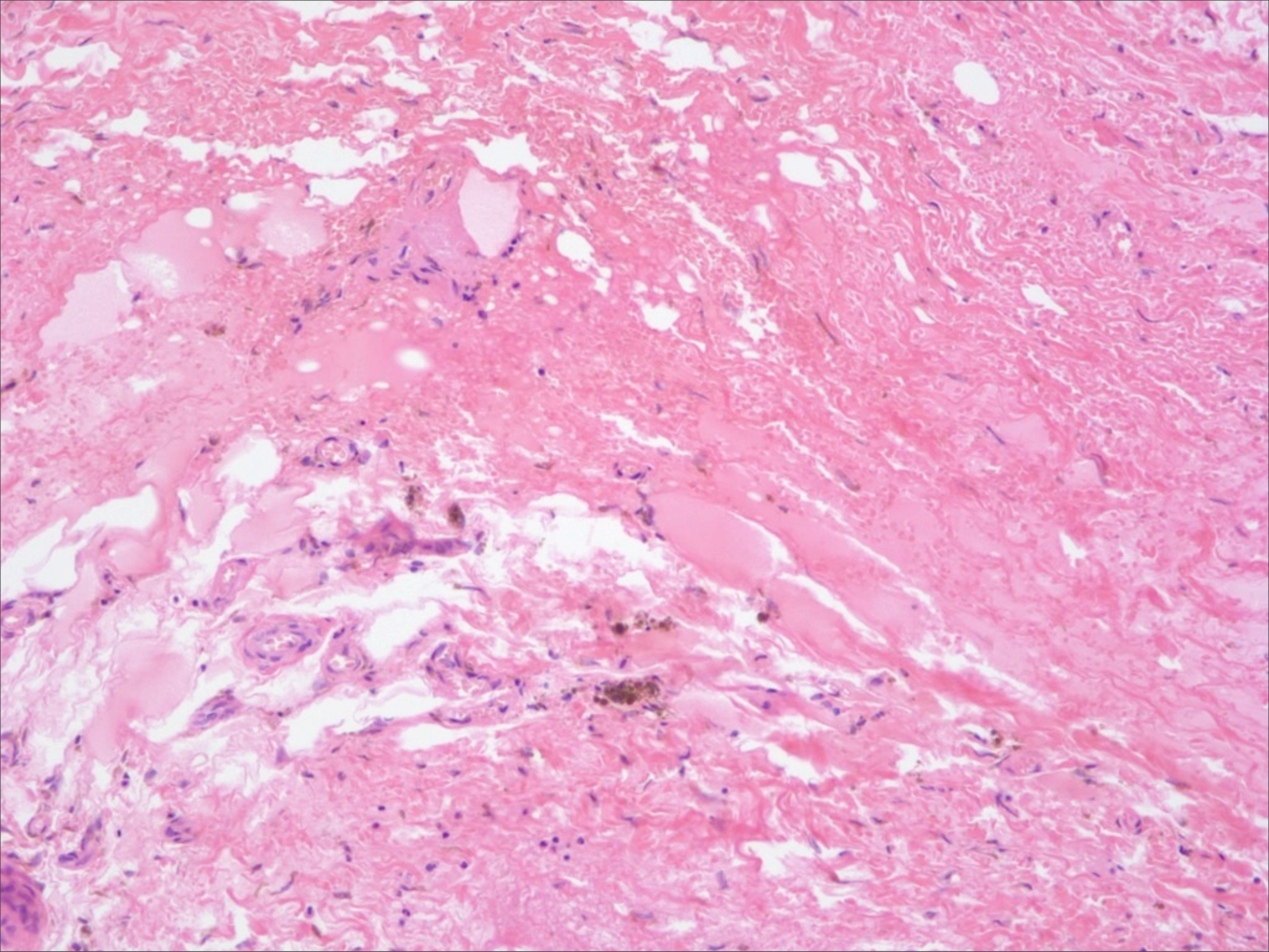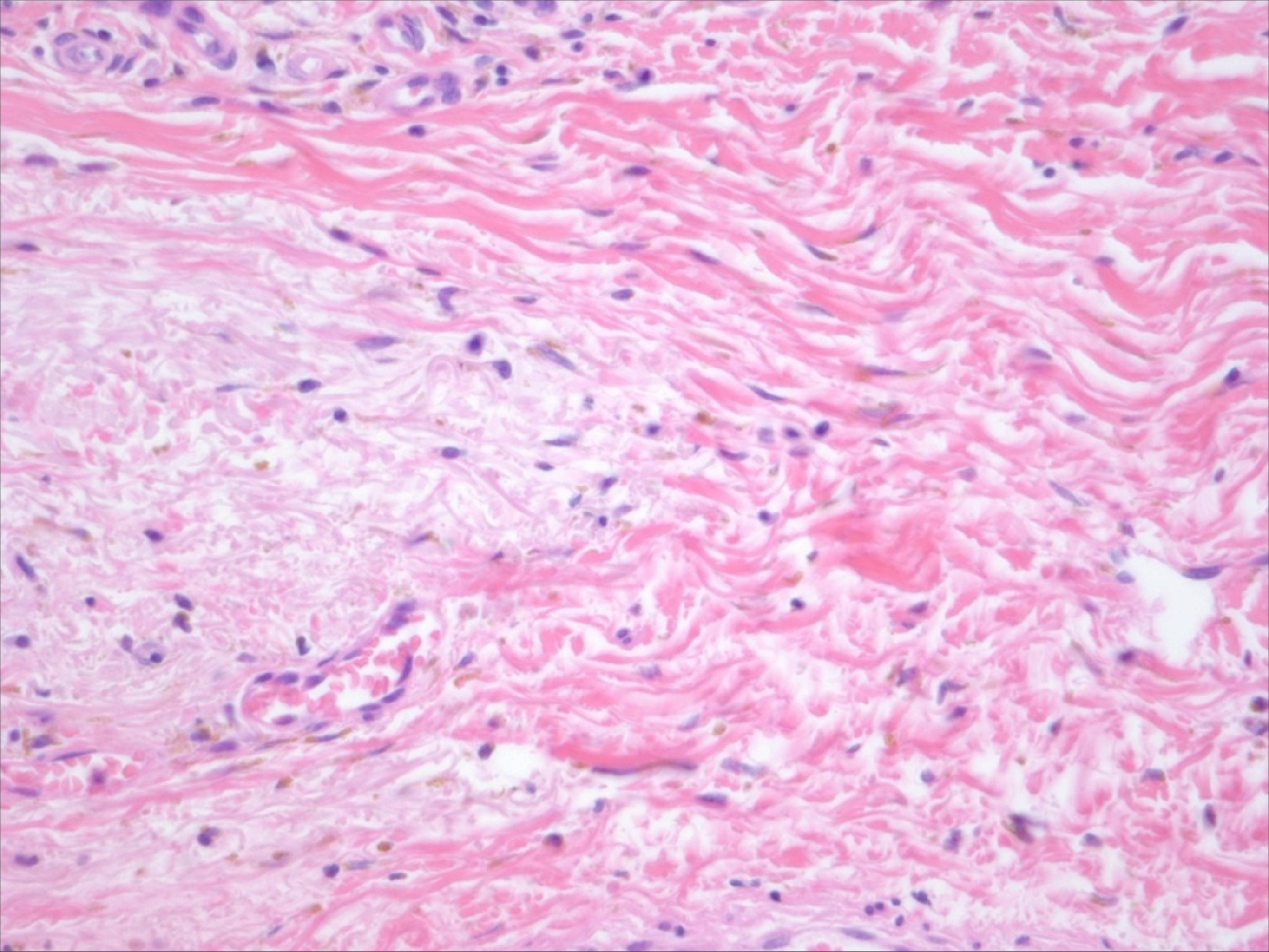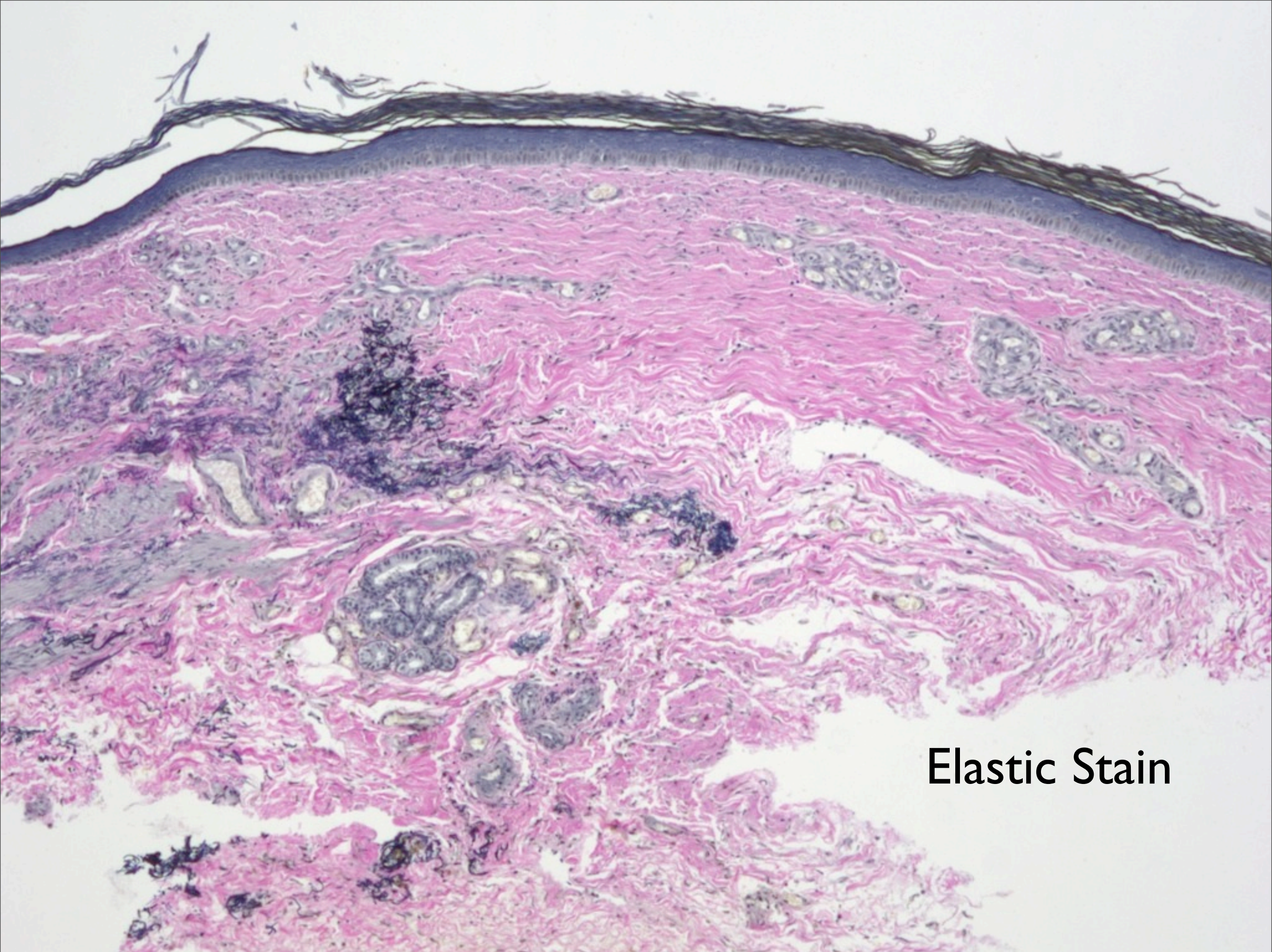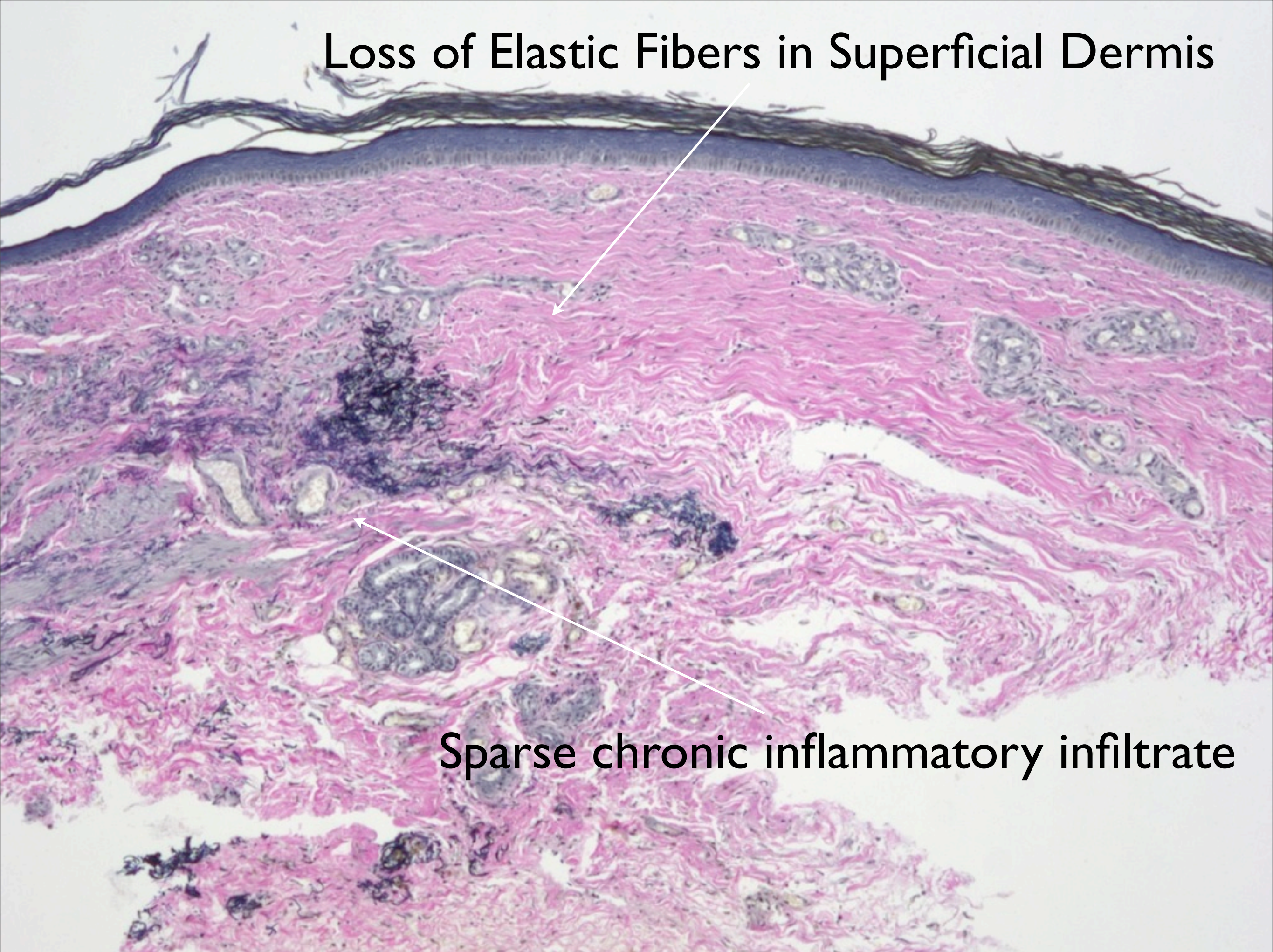
Elastic Stain



# Cutis Laxa



# Loss of Elastic Fibers in Superficial Dermis



Sparse chronic inflammatory infiltrate